

# Giant Dumbbell Urethral Calculus Secondary to Urethral Stricture: Hard Nut to Crack?

\*Manjeet Kumar<sup>1</sup>, Kirti Rana<sup>2</sup>, Sanjeev Chauhan<sup>2</sup>, Kailash Barwal<sup>1</sup>, Girish Sharma<sup>1</sup>, Pamposh Raina<sup>1</sup>

<sup>1</sup>Department of Urology, IGMC, Shimla, India.

<sup>2</sup>Department of Radiology, IGMC, Shimla, India.

\*Correspondence: dr.vicky.surgeon@gmail.com

Received: Mar 20, 2021; Accepted: Mar 30, 2021

**COPYRIGHT:** Kumar *et al.* This is an open-access article published under the terms of Creative Commons Attribution License (CC BY). This permits anyone to copy, distribute, transmit, and adapt the work, provided the original work and source are appropriately cited.

**CITATION:** Kumar M, Rana K, Chauhan S, Barwal K, Sharma G, *et al.* Giant Dumbbell Urethral Calculus Secondary to Urethral Stricture: Hard Nut to Crack? Recent Adv Biol Med. 2021; 7(1): 9800006. DOI: 10.18639/RABM.2021.9800006

## ABSTRACT

Urethral calculi are uncommon diagnoses. Large urethral stones with peculiar shapes have been reported. Management of such large stones depends upon size, shape, position, and associated abnormality of the urethra. We present a case of dumbbell-shaped large calculus secondary to bulbar urethral stricture. The patient was managed with Suprapubic cystotomy and antibiotics. Retrograde-urethrograph and micturating cystourethrograph showed bulbar urethral stricture. Trans vesical removal of stone was attempted; however, lower part of the calculus was impacted. Perineal retrieval of the calculus was done, followed by stage 1 urethroplasty with perineal urethrostomy. After three months, stage 2 urethroplasty was done.

**KEYWORDS:** Urethral Calculi; Dumbbell; Urethral Stricture; Urethroplasty.

## 1. INTRODUCTION

Urethral calculi are an uncommon presentation of lower urinary tract lithiasis. The incidence of urethral calculi is 0.3%. These lower urinary tract calculi more prevalent in lower socioeconomic status [1,2]. We present diagnosis and management of large dumbbell urethral stone with bulbar urethral stricture.

## 2. CASE SUMMARY

A 35-year-old male presents with dysuria, occasional hematuria, perineal pain. The patient gave a history of urethral instrumentation for urethral stricture. Blood investigations were normal; urine culture was *E coli* sensitive to fluoroquinolones. X-ray pelvis showed a large dumbbell urethral stone. Retrograde urethrograph showed bulbar urethral stricture, and dumbbell-shaped stone with one part in the prostatic urethra and the other in proximal bulbar joined by narrow membranous part. The patient was started on oral antibiotics, and a suprapubic cystostomy was done. The patient was planned for urethroscopy with or without Optic internal urethrotomy. However, in view of impacted urethral calculus along with bulbar urethral stricture, open surgery was planned. The patient was laid in the lithotomy position. Trans vesical removal of stone was attempted; however lower part of the calculus was impacted. The urethra was dissected till the membranous urethra. stone was removed with the removal of unhealthy mucosa. The reason for the failure of the endoscopic approach was the size, shape of calculus, and urethral stricture.

## 3. DISCUSSION

Urethral calculi have a bimodal age presentation first and the fourth decade of life [1,2]. Urethral calculi are of two types primary and secondary. Primary urethral calculi are formed within the urethra, and secondary calculi are calculated migrated from upper urinary tracts [3].

True Primary urethral calculi are small multiple and rarely symptomatic. Primary calculi could form in the urethra as a result of anatomic abnormality e.g., benign hyperplastic hyperplasia, diverticulum, stricture, stenosis, foreign body. They are more common in males compared to females due to the long urethra. They do not have a nucleus and are composed of magnesium ammonium phosphate. Stasis of urine secondary to infection, obstruction, stagnation causes condensation of concentrated urine. Occasionally foreign bodies act as a nidus for stone formation. Urethral calculi are composed of triple phosphate most commonly followed by calcium phosphate, uric acid, etc [4].

Children from underdeveloped countries present with urethral calculi due to underlying nutritional deficiencies. The predisposing factors for urethral calculi are stagnation, infection, obstruction, nutritional deficiencies [5]. Secondary urethral calculi are migratory are more common. They are usually composed of calcium oxalates. They get impacted at narrowing like meatus, before stricture, membranous urethra. Swift Joly has classified stones lodged in the posterior urethra into three different categories [6].

### 3.1. VESICO-URETHRAL STONES

These stones lie in the bladder and prostatic urethra.

### 3.2. URETHRAL STONES

These stones lie entirely in the urethra.

### 3.3. URETHRO-PROSTATIC STONES

These stones lie in the prostatic urethra and posterior bulbar urethra.

Patients with recent impaction of calculus present with acute urinary retention, strangury, hematuria, and dysuria; however, patients with chronic urethral calculi will present with lower urinary tract symptoms. Calculi within urethral diverticula may be either singular or multiple. Their natural history is often insidious, with minimal obstructive symptoms. Rather, a protracted course of increasing lower abdominal, pelvic, and perineal discomfort, as well as hematuria, dysuria, and dyspareunia, is often the norm [4].

Treatment of urethral calculi is largely determined by their location, size, shape, and urethral abnormality e.g., stricture, diverticulum. Small calculi, especially posterior urethral location, may be pushed into the urinary bladder and fragmented with cystolithotripsy. Small impacted urethral calculi can be fragmented within the urethra. Stones located in the posterior urethra may be pushed back into the bladder for subsequent fragmentation with electrohydraulic or laser lithotripsy, a procedure that includes a success rate of 66% to 86% [2,4]. The associated abnormality will require correction to prevent the recurrence of urethral calculi. Stone relocation into the urinary bladder from the anterior urethra is rarely feasible. Milking of smooth stone sometimes successful. Cystoscopic retrieval with fragmentation with lithotripsy is attempted. In case of failure, meatotomy or urethrotomy is always successful with the repair of the urethra.

Stones associated with urethral stricture are managed by optic internal urethrotomy followed by stone retrieval. In stricture not amenable for OIU, open incision and urethroplasty should be performed.

Our patient had dumbbell-shaped urethral calculus in the prostatic and proximal bulbar urethra with urethral stricture. The stricture was long; hence open removal followed by stage urethroplasty was done. Urethral closure was done in the 2nd Stage procedure at three months.

## 4. CONCLUSION

This case highlights a rare case of urethral stone with dumbbell shape managed by combined abdominal and perineal retrieval of urethral calculus.

## CONFLICT OF INTEREST

None.

## REFERENCES

1. Aegukkatajit S. Reduction of urinary stone in children from north-eastern Thailand. *J Med Assoc Thai.* 1999; 82:1230-1233.
2. Verit A, Savas M, Ciftci H, Unal D, Yeni E, *et al.* Outcomes of urethral calculi in patients in an endemic region and an undiagnosed primary fossa navicularis calculus. *Urol Res.* 2006; 34:37-40.
3. Menon M, Martin IR. Urinary lithiasis: etiology, diagnosis, and medical management. In: Walsh PC, Retik AB, Vaughan ED Jr, Wein AJ, editors. *Campbell's Urology.* 8th ed 2002; Saunders Philadelphia, 3288-3289.
4. Kamal BA, Anikwe RM, Darawani H, Hashish M, Taha SA. Urethral calculi: presentation and management. *BJU Int.* 2004; 93:549-552.
5. Subbarao P, Lal R, Bhatnagar V, Mitra DK. Multiple urethral calculi in children: report of two cases. *Surg Today.* 1998; 28:1210-1212.
6. Barrett JC. Giant prostatic calculi. *Brit J Surg.* 1957; 45:267-269.

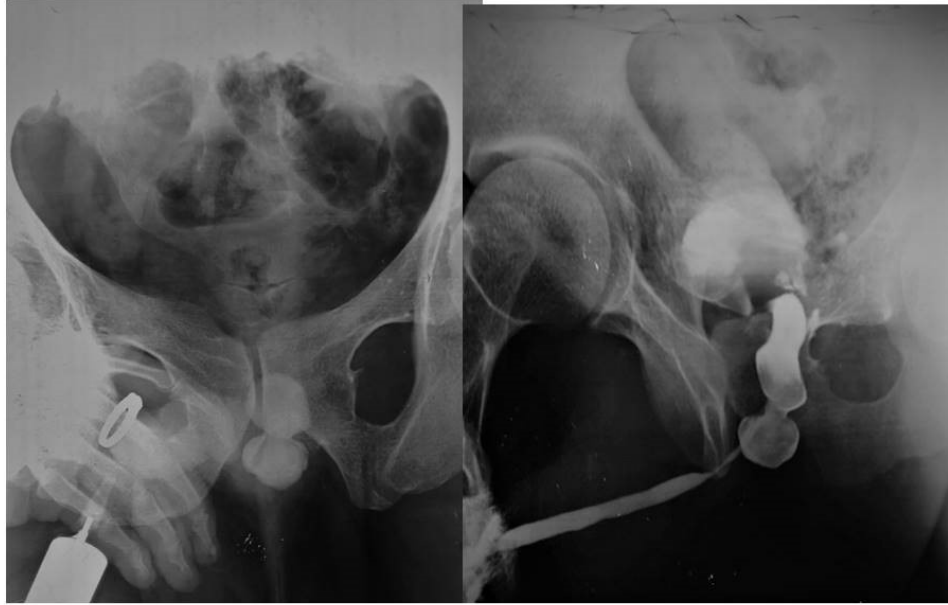

Figure 1. Xray Pelvis a. Plain xray show dumbbell shaped calculus in pelvis  
b. retrograde urethrogram show contrast going into urinary bladder

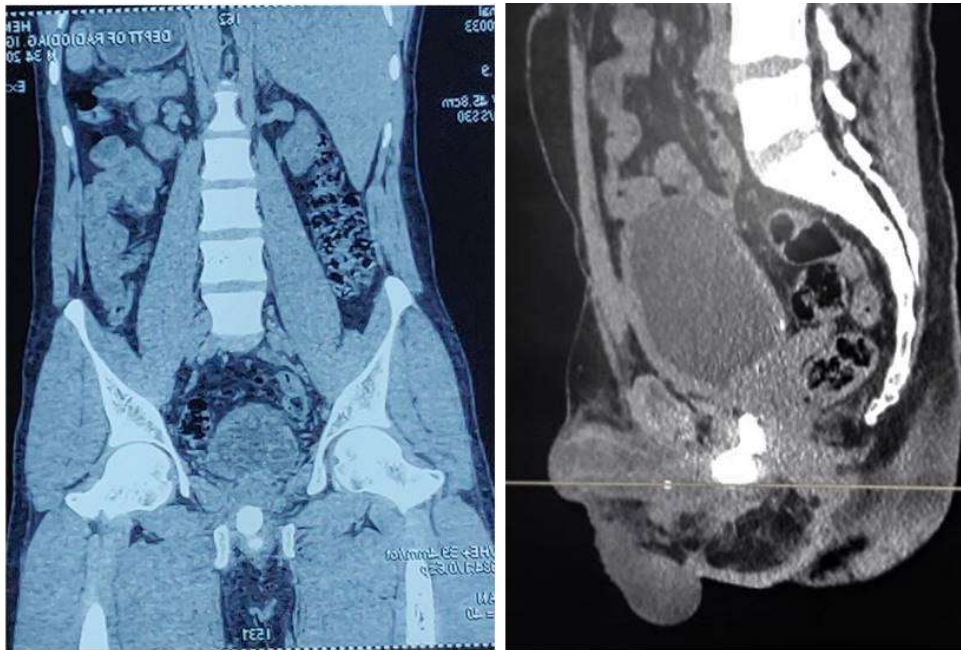


Figure 2. Non contrast CT scan a. Saggital section b. coronal section showing  
dumbell urethral calculus

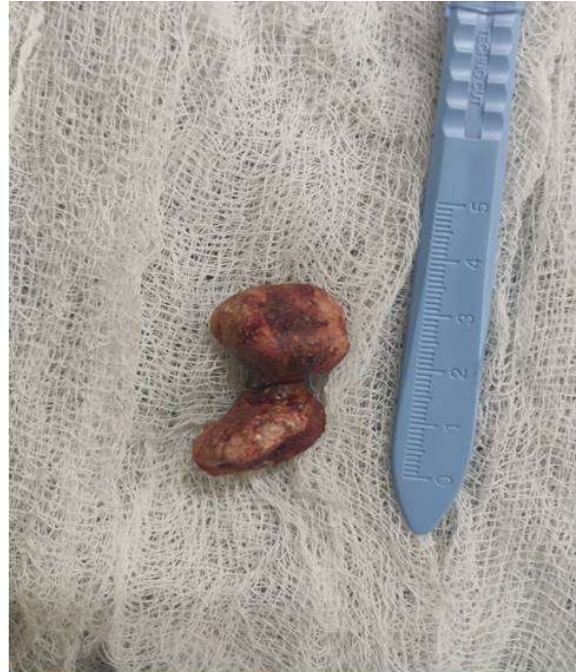

Figure 3. Postoperative picture show dumbbell shaped calculus 3.5 x 1.5 cm