

E-ISSN: 2378-654X

Recent Advances in Biology
and Medicine

Review Article

Cervical Spondylotic
Myelopathy: Pathophysiology
and Surgical Approaches

HATASO, USA

Cervical Spondylotic Myelopathy: Pathophysiology and Surgical Approaches

Putu Eka Mardhika^{1*}, Ketut Kris Adi Marta¹, Sri Maliawan², Tjokorda GB Mahadewa²

¹Faculty of Medicine, Udayana University, Bali, Indonesia.

²Neurosurgery Department, Faculty of Medicine, Udayana University, Sanglah Public General Hospital of Denpasar, Bali, Indonesia.

*Correspondence: ekamardhika@gmail.com

Received: Jul 20, 2017; Accepted: Aug 24, 2017

Abstract

This paper reviews the pathophysiology of cervical spondylotic myelopathy (CSM) and several surgical approaches for the treatment of CSM. CSM is a degenerative disease with severe morbidity. The pathophysiology of CSM involves static, dynamic, and ischemic factors. The management of mild CSM typically involves conservative treatments and medication; whereas, moderate and severe CSM are better treated surgically. Surgical treatments for CSM are basically classified into anterior and posterior surgeries. The common techniques are anterior cervical discectomy and fusion (ACDF), anterior cervical corpectomy and fusion (ACCF), laminectomy, and laminoplasty. Each technique has its own advantages and disadvantages. In this paper, we review the research papers from PubMed database to elaborate the advantages and disadvantages of each technique.

Keywords: Cervical spondylotic myelopathy; Pathophysiology; Anterior surgery; Posterior surgery.

1. INTRODUCTION

Increased human's lifespan increases the prevalence of degenerative disease. Cervical spondylotic myelopathy (CSM) is the most common degenerative disease that causes severe morbidity. There are several theories that elaborate the pathophysiology of CSM that basically cause anterior and posterior pathologies.

The managements of CSM include conservative treatments, medication, and surgery. However, for moderate and severe myelopathy, surgery is the choice of treatment to prevent further damage to the spinal cord. It can be performed using either the anterior approach or the posterior approach. Each approach has its own advantages and disadvantages.

This paper reviews the pathophysiology of CSM and several surgical approaches to treat patients with CSM. We focused on the most common techniques used, which includes anterior cervical discectomy and fusion (ACDF), anterior cervical corpectomy and fusion (ACCF), laminectomy, and laminoplasty. The research papers were searched on the PubMed database using the keywords "cervical spondylotic myelopathy pathophysiology," "laminoplasty," "laminectomy," "anterior cervical discectomy," and "corpectomy." We selected only the full text research papers that were published between 2007 and 2017; a total of 48 papers were found related to our topic.

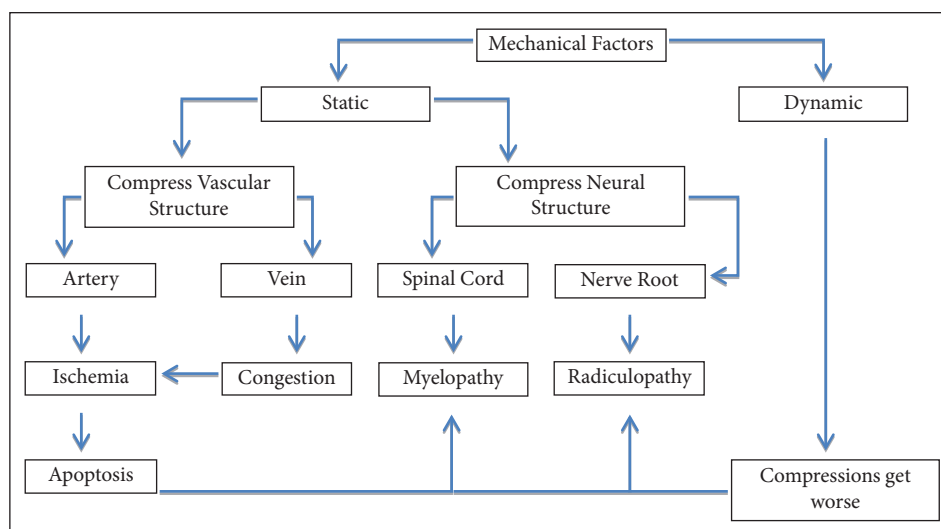
2. CERVICAL SPONDYLOTIC MYELOPATHY

CSM is the most common degenerative disease that causes myelopathy of the cervical spine [1]. It begins with the degeneration of the cervical disc and is followed by the intervertebral disc collapse [1, 2]. Initially, the disc shrinks at the ventral part, which forms a kyphotic deformity. This, in turn, reduces the sagittal diameter of the spinal canal. Further, the disc shrinks at the dorsal part and causes protrusion of intervertebral disc into the spinal canal. The herniated disc causes the posterior longitudinal ligament to peel away from the vertebral bodies endplate [2]. As a consequence, the endplate of the vertebral bodies start to form osteophyte as a compensation of the high mechanical stress caused by the hypermobility of the cervical spine [1, 2].

As shown in Figure 1, mechanical factors and ischemia are the two factors that contribute to the development of CSM [1]. The mechanical factors are classified further into static and dynamic mechanical factors [1-6].

The static factors are structural spondylotic abnormalities that cause the narrowing of the spinal canal. This abnormal structure can directly compress the spinal cord and cause myelopathy [1-3, 7]. The static factors include osteophyte formation, hypertrophy of the flavum ligament, ossification of posterior longitudinal ligament (OPLL), disc herniation, congenital canal stenosis, kyphosis, and spondylolisthesis [1, 2, 5, 6]. Posterior disc osteophyte were the most common factor to cause narrowing of spinal cord in the elderly [8].

The dynamic factors are abnormal and repetitive motions of the cervical spine [1, 3, 6, 7]. The dynamic factors combined with the static factors can severely injure the spinal cord [1, 2, 5]. The spinal cord that is already compressed will be even more compressed owing to the repetitive abnormal motion. The flexion of the cervical spine can lead to the compression of the

Figure 1: Pathophysiology of cervical spondylotic myelopathy.

spinal cord by osteophyte formation and kyphosis deformity, which makes the symptom even worse [1-3]. On the other hand, the extension of the cervical spine can lead to compression by hypertrophy of flavum ligament [1, 2]. According to MRI images, the cervical spine extension can increase canal stenosis two times more than the flexion motion [2, 3].

The abnormal spondylotic elements can directly compress the vascular systems that supply the spinal cord [1, 6]. They can directly compress the arteries such as the anterior spinal artery, posterior spinal artery, radicular arteries, pial plexuses, and penetrating spinal cord vessels, which further cause ischemia [2]. Ischemia or hypoxic condition combined with the inflammatory response can cause neuron and oligodendrocytes apoptosis [4, 6]. If the abnormal elements compress the vein, they can cause venous congestion, which may further develop into ischemia [4]. All of these theories are supported with evidence from postmortem studies, which found necrosis and grey matter cavitations in the spinal cord. It makes the vascular pathologies to be more involved [1, 2].

3. ANTERIOR SURGICAL APPROACH

Anterior surgical approaches are preferred for the treatment of anterior pathologies that involve 1-2 vertebral bodies. Anterior surgeries exhibit better correction of cervical lordosis than posterior surgeries [9]. This is probably because these approaches allow adjustment of cervical angle with placement of graft.

Several studies demonstrated that anterior surgeries exhibit higher postoperative Japanese Orthopedic Association (JOA) score than posterior surgeries, indicating a better postoperative neural function. However, both approaches resulted in the same neural function recovery rate at 5 years follow-up [10, 11]. This is because anterior surgeries allow direct removal of anterior pathologies that cause compression to the spinal cord.

However, the high incidence of complication is one of the primary limitations of the anterior surgeries. Nevertheless, it was found that in more than 5 years post operation, the complication rate was similar between anterior and posterior surgeries [10]. The most common complication found following anterior surgeries is pseudoarthrosis [11]. The authors [11] suggested that this is due to the technical reasons and bone graft quality.

3.1. Anterior Cervical Discectomy and Fusion

ACDF is a technique that allows the direct removal of the disc material and posterior osteophytes compressing the spinal cord or nerve roots at the level of the disc space. It is performed with patient in a supine position and neck in a slight extension position. A transverse incision is then made on the anterolateral aspect of the neck. The dissection is made through the fascia plane between the carotid artery sheath laterally and trachea medially. This approach allows the surgeon to access the cervical intervertebral disc and perform a discectomy. Following that, the intervertebral disc space is distracted, and the height is restored with the placement of a graft [12].

3.1.1. Clinical Outcome

In general, ACDF provides good clinical outcome as a treatment of CSM. ACDF improved the modified JOA scores and Nurick grades postoperatively [13, 14]. Moreover, several studies reported that this technique provided higher postoperative JOA

scores [9, 15-19]. In addition, this technique improved the pain symptom in the short term of follow-up [14, 20, 21]. Based on these results, ACDF seems to result in adequate decompression to the spinal cord and good recovery of neural function.

3.1.2. Radiological Outcome

The radiological outcome seems related with the implants that is used during operation. In this paper, we elaborate the radiological outcome of ACDF with different implants.

ACDF implants was developed in the 1950s; they were initially introduced by Cloward, Robinson, and Smith. In their early development, Cloward introduced dowel autograft implant; whereas, Robinson and Smith introduced horseshoe autograft implant to achieve fusion. The autograft was harvested from the patient's iliac crest bone. In 1960, Bailey and Badgley developed a different type of autograft called the onley struts graft and continued by Simmons and Bhallain (1969), who introduced the keystone graft that improved stability and fusion by increasing the distraction height [22].

Autogenous graft was effective to achieve fusion. However, it exhibits several disadvantages such as pain at the graft site, infection, hematoma, nerve injury, and deformity or fracture of the iliac bone. All of these complications led to the development of cage implant. In 1988, Bagby introduced Bagby Bone Basket, which was the first cage implant. It was a cylindrical device made of fenestrated and hollow stainless steel. In the following years, cage implant designs developed continuously and were classified into screw cage, box shape, and vertical ring designs [22].

Stand-alone design was effective in single level ACDF; however, it was not effective in multilevel ACDF. Since 1970, anterior plating was developed to reduce pseudoarthrosis and the risk of nonunion [22]. Han *et al.* [20] demonstrated that the incidence of segmental subsidence was higher in the stand-alone cage (36.1%) than in the plate assisted ACDF (15.6%). However, the average segmental subsidence in the anterior plate and the stand-alone cages were 4.57 and 4.28 mm, respectively, at 12 months follow-up post surgery [20]. Haghnegahdar *et al.* [14] also reported a high incidence of subsidence (19%) in the stand-alone cage. The incidence of cervical kyphosis was higher in ACDF with stand-alone cages (27.8%) compared to ACDF with anterior plate (8.9%) [20]. This suggests that the anterior plating is more superior to stand-alone cages in decreasing the subsidence rate and improving the cervical lordosis.

Nowadays, the focus of improvement in cage design is the streamlining of anterior plating into the stand-alone cage. The most recently developed cage implant is the zero profile implant. It utilizes an integrated and low profile plate design to avoid implant-to-soft tissue impact [22]. Alimi *et al.* [13] reported that the zero profile implant exhibited lesser postoperative soft tissue thickness than the anterior plate. This indicates that the zero profile implant may reduce the irritation of the surrounding soft tissues compared with the anterior plate. However, both of them provided a good fusion rate.

3.1.3. Surgical Outcome

ACDF exhibits several postoperative complications. Haghnegahdar *et al.* [14] performed ACDF with PEEK stand-alone cage and reported the occurrence of postoperative complications including hoarseness (4.4%), C5 root palsy (1.5%), and dysphagia (1.5%).

The primary complications after ACDF with anterior plate are chronic dysphagia and prevertebral soft tissue swelling [13, 22]. The mechanism for these complications are still not well understood; however, it is proposed that retraction during surgery, direct pressure to the esophagus by the anterior plate, and irritation of the surrounding soft tissues may contribute to the complications occurring post ACDF with anterior plate [13]. Alimi *et al.* [13] demonstrated that the zero profile implant was more superior to the anterior plate in reducing the dysphagia score. Fengbin *et al.* [23] conducted a randomized prospective study to identify the approach that should be used to reduce dysphagia postoperatively. They reported that, during the Smith–Robinson approach, the lateral edge of the omohyoid should be selected when the surgeon targets the C3–C4 vertebrae; whereas, the medial edge of the omohyoid should be selected when the C6–C7 vertebra is the level target.

Another complication of ACDF is the postoperative neck pain. A study by Ha *et al.* [24] found that the amount of distraction correlates with the postoperative neck pain. Distraction with high torque (>6 kgf.cm) increases the risk of neck pain on the first and third day post operation. The authors [24] suggested that distraction above 6 kgf.cm should be avoided to reduce the risk of postoperative neck pain.

3.2. Anterior Cervical Corpectomy and Fusion

Corpectomy is a technique to treat CSM by removing the central portion of the vertebral body. This technique is an alternative procedure if multiple discectomies are required, and when a large access area is required to decompress the spinal cord by removing the pathologies adjacent to the vertebral body. After corpectomy is performed, iliac crest bone autograft, fibular strut allograft, or metallic cages can be used to fill the defect [12].

3.2.1. Clinical Outcome

ACCF is an effective treatment for CSM. Several studies showed that this technique increased the JOA score postoperatively in the mid-term of the follow-up [9, 15-19, 25]. Lu *et al.* [8] also reported a good clinical outcome of ACCF in the elderly population (>70 years old). The recovery rate of this technique was considerably high, and was reported to be greater than 50% [8, 25]. These studies showed that ACCF resulted in good clinical outcomes and adequate decompression for patients with CSM.

Regarding the prognostic factor, Gao *et al.* [25] found that late onset symptoms (>12 months), low preoperative JOA score (<9), and presence of high intensity signal in spinal cord were associated with lower recovery rate.

3.2.2. Radiological Outcome

ACCF results in a good radiological outcome postoperatively. In terms of cervical angle, ACCF increased the entire cervical lordotic angle postoperatively [16-18, 25]. In elderly person, ACCF resulted in the same enhancement of cervical angle when compared with non-elderly [8]. Furthermore, ACCF also increased the sagittal segmental angle [17, 18, 25]. In addition, Gao *et al.* [25] reported that 2 levels ACCF provided more lordotic curve than 1 level ACCF. The authors [25] argued that this was probably due to the fixation of longer prevertebral curve plating in 2 levels ACCF. On the other hand, Chacko *et al.* [26] reported that oblique corpectomy without fusion has the tendency to reduce the lordotic angle. Therefore, it seems that the anterior plate and graft placement have important roles in maintaining the cervical lordotic angle in ACCF.

The spinal fusion rate in ACCF was satisfied [9, 15, 17, 18, 25]. A retrospective study with a minimum of 5 years follow-up reported that the overall spinal fusion after ACCF was 96.6% [25]. Furthermore, this paper [25] reported that there was no difference in the fusion rate between the iliac crest bone graft and the Titanium Mesh Cage (TMC) filled with local vertebral body autograft.

3.2.3. Surgical Outcome

There are several complications following the ACCF procedure. Several studies showed that graft complication, dysphagia, and dysphonia were the primary complications of this technique [10, 18]. Gao *et al.* [25] reported that graft subsidence (TMC) occurred in 11.1% of the patients. However, there was no difference of incidence in 1 level and 2 level corpectomies. Moreover, they reported that the chronic neck pain occurred in 15.9% of the patients [25]. In elderly subjects, ACCF caused complications such as pulmonary infection, injury of the spinal duramater, and injury of the vertebral artery [8].

3.3. Comparison

3.3.1. Clinical Outcome

Several studies compared the clinical outcomes of the ACDF and ACCF techniques. The parameters of the clinical outcome in these studies were JOA score, visual analog scale (VAS) score, neck disability index (NDI) score, Odom criteria, and hospital length of stay (HLOS).

JOA score is an indicator to rate the severity of cervical compressive myelopathy. Several studies reported that both techniques provide higher postoperative JOA score. However, the difference was not significant in the short-term and mid-term of follow-up [9, 15-19]. This indicates that both procedures provide adequate decompression of the spinal cord in CSM and provide good neural recovery in the short-term and mid-term of the follow-up.

The VAS score is a common indicator to rate pain. Meta-analysis showed that both techniques reduced the VAS scores significantly after operation in short-term and mid-term of follow-up. However, the difference between both techniques was not significant [15, 17-19]. This indicates that both techniques reduce pain symptom equally.

The NDI score is an indicator to assess disability, 0% indicates no limitation of activity while 100% indicates complete limitation. Several studies used the NDI score as a parameter of clinical outcome. They reported that both techniques improved the NDI score postoperatively [16, 18].

An Odom criterion is an indicator to assess improvement after the operation. The Odom criteria were analyzed between both procedures. Han *et al.* [18] reported that both procedures provide good and excellent clinical outcome equally. "Good" indicates minimal persistence of preoperative symptoms, while "excellent" indicates relive of all preoperative symptoms and improvement of abnormal findings.

Several meta-analysis studies reported that ACDF provided shorter HLOS than ACCF [9, 15, 18]. The authors propose that the long HLOS in ACCF may be because the patients who received ACCF may suffer from more severe spinal cord injury than ACDF [9]. On the other hand, meta-analysis studies by Wang *et al.* [16] and Huang *et al.* [17] reported that both procedures resulted in the same HLOS.

3.3.2. Radiological Outcome

Several studies compared the radiological outcomes of ACDF and ACCF. The parameters of the radiological outcome in the studies are fusion rate, cervical angle, and segmental angle.

Meta-analysis studies reported that both techniques exhibited the same high fusion rate [9, 15, 17, 18]. On the other hand, the meta-analysis study by Wang *et al.* [16] reported that the fusion rate in ACDF was better than that in ACCF in the multilevel CSM.

Several studies measured the cervical angle to elaborate the radiological outcomes of ACCF and ACDF. They reported that both techniques improved the cervical lordotic angle. However, ACDF resulted in the better improvement of cervical lordotic angle than ACCF [16-18]. The segmental angle also improved to be more lordotic in both procedures. However, ACDF was more superior to ACCF in terms of segmental lordosis [17, 18].

3.3.3. Surgical Outcome

We found several studies that compared the surgical outcomes of ACDF and ACCF. The parameters were operation time, blood loss, and complication rate.

Several meta-analysis studies showed that ACDF provides shorter operation time than ACCF [9, 17]. Furthermore, a study by Fei *et al.* [15] reported that ACDF exhibited an average of 26.9 mi less in operation time than ACCF. The authors [15] argue that the longer operation time in ACCF may be due to the complex and challenging nature of the procedure. On the other hand, other meta-analysis studies reported that the operation time was the same in both procedures [16, 18, 19].

Several studies used blood loss as a parameter to measure the surgical outcome; lower blood loss can improve the clinical outcomes. Meta-analysis studies showed that ACDF exhibited less perioperation blood loss than ACCF [9, 16-19]. Furthermore, the meta-analysis by Fei *et al.* [15] found that ACDF exhibited an average of 119.63 ml less blood loss than ACCF. All of these studies showed that ACCF exhibited higher intraoperative blood loss. This is because the ACCF is a decompression technique with the removal of vertebral body that is more invasive and complex than ACDF technique.

The complications that were reported between both techniques were donor site pain, graft dislodgment, C5 palsy, titanium mesh subsidence, dysphagia, hoarseness, hematoma, pseudoarthrosis, cerebrospinal fluid leaks, and infection. It has been reported that ACCF exhibited higher complication rate than ACDF [15, 16, 18]. Moreover it has been found that graft subsidence incidence and C5 palsy were higher in ACCF [16]. Wang *et al.* [27] analyzed the literature for the last decade and found that ACDF exhibited the lowest rate of C5 palsy incident.

Dysphagia is a common complication of anterior surgeries. A meta-analysis study showed that the incidence of dysphagia was higher after ACDF when compared with that after ACCF. However, the incidence of Cerebral Spinal Fluid (CSF) leakage and infection was lower in ACDF [27].

However, other meta-analysis study by Huang *et al.* [17] reported that the complication rate in both procedures were the same.

4. POSTERIOR SURGICAL APPROACH

Posterior surgical approaches are preferred in CSM with pathologies in more than two vertebral bodies without kyphotic alignment [9, 28]. Posterior approaches need lordotic alignment to allow the spinal cord to shift posteriorly after decompression.

4.1. Laminectomy

Laminectomy is performed with the patient in a prone position. Posterior midline incision is performed to expose the vertebra. Decompression is achieved by removing the spinous process and lamina on the level of compression. This technique provides direct decompression in the CSM patients with posterior structure abnormality; whereas, in anterior structure abnormality, this technique decompresses indirectly with the posterior shift of the spinal cord [28]. Laminectomy is typically accompanied by fusion and instrumentation to stabilize the spine [12].

4.1.1. Clinical Outcome

Laminectomy is an effective treatment to treat multilevel CSM. Laminectomy resulted in the enhancement of the JOA score post operation and above 50% of the recovery rate [28-31]. These studies indicate that this technique provides adequate decompression to the spinal cord.

Jain *et al.* [28] concluded that younger age (<57 yo), early onset of symptoms (<4 months), and high preoperative JOA score (>10) exhibit better neurological outcome.

4.1.2. Radiological Outcome

Laminectomy tends to reduce the cervical lordotic angle [32, 33].

4.1.3. Surgical Outcome

The most common complication of posterior approach is the postoperative axial neck pain. A study by Zhang *et al.* [29] reported that preserving the C7 spinous process during laminectomy reduces the risk of postoperative axial neck pain. Moreover, the authors [29] found that the axial neck pain is correlated with musculature atrophy after the procedure. Another complication of laminectomy is C5 palsy [30, 31].

4.2. Laminoplasty

Laminoplasty is performed in the same patient position as laminectomy. Posterior midline incision and stripping the paraspinal muscle are performed to expose the vertebra. Laminoplasty can be performed with single-door technique or double-door technique. Single-door technique was first described by Hirabayashi in 1978. The technique is performed by completely dividing the junction of the lateral mass and lamina on one side. On the other side, a gutter is made until it reaches the anterior cortex. The complete site then rotates to the contralateral site by using the partial site as a hinge [7, 12].

Kurokawa described the double-door or french-door laminoplasty in 1982. It is performed by midline osteotomy through spinous process and lamina. The gutter is made as a hinge at the junction of the lateral mass and lamina on both lateral sides. After that, the lamina are opened in the midline; both lateral sides are used as a hinge. The surgeon can use the instrument or bone graft to maintain the lamina in an open position [7, 12].

4.2.1. Clinical Outcome

Several retrospective studies demonstrated that laminoplasty results in good clinical outcomes. Most of these studies used the JOA score as a parameter of clinical outcome. They reported that laminoplasty provided significant enhancement of the JOA score in the short-term, mid-term, and long-term follow-up [34-39]. However, Sakaura *et al.* [40] reported that the average JOA score was at its highest point in 12 months of follow-up and decreased slightly to 14.9 in the final follow-up. In this paper [40], they explained that this was due to the non-CSM diseases including lumbar spine canal stenosis, osteoarthritis of knee, carpal tunnel syndrome, and stress urine incontinence. Moreover, Son *et al.* [41] reported that laminoplasty resulted in good clinical outcomes in the elderly (>65 years old), which were the same as in the non-elderly subjects. Similarly, Heller *et al.* [42] reported that both laminoplasty approaches exhibited similar good clinical outcomes.

Furthermore, the recovery rate (RR) of laminoplasty was greater than 50% in the short-term, mid-term, and long-term follow-up [35, 38-41]. On the other hand, Uehara *et al.* [34] reported that RR was 47.1% in the final follow-up, but 55.9% immediately after operation. They did not explain the reason for this result, but it was probably because they included patients with cervical instability that were more complex. In addition, the sample size was smaller ($n = 13$) compared to other studies.

Similarly, several studies used the NDI score as a parameter of clinical outcome and reported that laminoplasty improved the NDI score within 1-2 years of post operation [39, 43]. Interestingly, Shin *et al.* [35] used the Frankel score to measure the clinical outcome of laminoplasty and found an improvement in the Frankel score from 3.93 to 4.53 at 12 months post operation. However, the difference was not significant.

Furthermore, Sun *et al.* [44] reported that double-door laminoplasty could alleviate the atypical symptoms of CSM that was called Barre and Lieou syndrome. The stimulation of sympathetic nerves by direct compression of spinal cord causes this syndrome. Double-door laminoplasty could alleviate vertigo, headache, nausea, tinnitus, and gastrointestinal discomfort.

The authors of these papers used different approaches of laminoplasty to provide decompression to the spinal cord. However, all of these techniques provide the same decompression technique by elevating the lamina.

4.2.2. Radiological Outcome

The most common post laminoplasty complication is the loss of cervical lordosis. Several studies reported that laminoplasty reduced the C2–C7 lordotic angle [34-37]. These studies used different laminoplasty methods to provide decompression of the spinal cord. It is suggested that the preservation of the C2 muscle attachment can maintain the post operation cervical lordosis angle [40]. Uehara *et al.* [34] used open door laminoplasty, and 84.6% of their cases involved the C3 level. However, they did not describe the preservation of the muscle attachment at the C2 level in the technique. Conversely, Cho [37] and Sakaura *et al.* [40] preserved the C2 muscle attachment in their technique, and this resulted in lesser loss of cervical lordosis than that reported by Uehara *et al.* [34]. Interestingly, Su *et al.* [36] reported lesser loss of cervical lordosis after performing C3–C6 laminoplasty without preserving the C2 muscle attachment. However, they used prebent nail rod to maintain the cervical curvature angle. Unfortunately, they did not measure the cervical Range of Motion (ROM), as prebent nail rod may reduce the cervical ROM. From these studies, it seems that the preservation of the C2 muscle attachment during laminoplasty provides lower risk of cervical lordotic angle loss (Table 1).

In addition, decreased cervical ROM is a common complication of laminoplasty. Several studies showed that laminoplasty reduced cervical ROM in various degrees [34, 35, 37-40]. As shown in Table 2, it seems that the preservation of C2 and C7 muscle attachments have an important role in the preservation of cervical ROM postoperatively. The study by Uehara *et al.* [34] demonstrated the highest loss of cervical ROM; the authors admitted that they did not preserve the C2 and C7 muscle attachment. Technique with preservation of C2 and C7 muscle attachment may reduce the risk of cervical ROM loss. Cho [37] demonstrated that they only preserved C2 muscle attachment; their study showed the lowest loss of cervical ROM. However, in their study, above 70% of their technique did not involve C7 in the extent of laminoplasty.

Two most common laminoplasty techniques are open-door technique and french-door technique, and both techniques provide adequate expansion of cervical canal post operation [35, 41, 45, 46]. However, several studies reported that open-door technique provided a wider expansion ratio than french-door technique in the C6 level and same expansion ratio in the C5 level [45, 46]. Unfortunately, the authors did not measure the expansion ratio in other levels. In terms of inclination angle enhancement, the french-door technique was more superior to the open-door technique in the C5 and C6 levels [46]. Based on these results, the open-door technique is more preferred in CSM with unilateral radiculopathy; whereas, the french-door technique is more preferred in CSM with bilateral radiculopathy.

4.2.3. Surgical Outcome

Axial pain is a common post operation complication of laminoplasty. We believe that the dissection of muscular attachment at C2 and C7 is the cause of this complication; the preservation of them can reduce postoperative axial neck pain. Mesfin *et al.* [43] demonstrated that by performing C4–C6 laminoplasty, the NDI pain subscore decreased from 1.3 to 0.7 at 1 year follow-up. The pain subscore was already low before the operation and became even lower at 1 year post operation. Yeh *et al.* [39] preserved the C2 and C7 muscle attachments and reported similar results with other studies. Similarly, Sakaura *et al.* [40] performed the C3–C6 laminoplasty and reported that the postoperative axial neck pain was 5% at 1 year and 0% at the final follow-up. They preserved the C2 and C7 muscle attachments in their operation technique. Mesfin *et al.* [43] suggested that if the compression

Table 1: Relation between C2 muscle attachment preservation to loss of cervical lordotic angle.

Study	n	Preservation of C2 muscle attachment	C2–C7 angle		% Loss
			Pre	Post	
Uehara <i>et al.</i> [34]	13	No	8.8°	5.3°	–39.8%
Shin <i>et al.</i> [35]	45	Not described	15.02°	9.69°	–35.5%
Cho [37]	32	Yes	13.4°	11.1°	–17.2%
Su <i>et al.</i> [36]	49	No	21.27°	20.09°	–5.5%
Yeh <i>et al.</i> [39]	65	Yes	13.9°	13.6°	–2.15%
Yeh <i>et al.</i> [38]	104	Yes	9.7°	9.5°	–2.1%
Sakaura <i>et al.</i> [40]	20	Yes	13.8°	19.2°	+39.1%

Table 2: Relation between C2 and C7 muscle attachment preservation to loss of cervical ROM.

Study	C2 muscle attachment preservation	C7 muscle attachment preservation	Cervical ROM		% Loss
			Pre	Post	
Uehara <i>et al.</i> [34]	No	No	37.8°	8.0°	78.8%
Shin <i>et al.</i> [35]	Not described	Not described	37.3°	23.3°	37.5%
Yeh <i>et al.</i> [38]	Yes	No	24.6°	15.9°	35.3%
Sakaura <i>et al.</i> [40]	Yes	Yes	37.2°	30.0°	19.35%
Yeh <i>et al.</i> [39]	Yes	Yes	34.9°	29.9°	14.3%
Cho [37]	Yes	No	44.3°	41.8°	5.6%

is at the C3 level, it is better to perform laminectomy in the C3 level than laminoplasty to preserve the C2 semispinalis cervicis. Nevertheless, both of these studies lack a control group; considerable controlled studies are essential.

A study showed that laminoplasty caused the C5 root palsy [10]. This could be due to the posterior shift of the spinal cord after the decompression.

4.3. Comparison

4.3.1. Clinical Outcome

Liu *et al.* [33] showed that both techniques increased the JOA score postoperatively and resulted in similar improvements in the VAS score.

Furthermore, Warren *et al.* [47] conducted a retrospective study to compare french-door laminoplasty and laminectomy and fusion. The parameter of clinical outcome was HLOS. They reported that laminoplasty provided shorter HLOS than laminectomy and fusion with an average of 3.7 and 5.9 days, respectively [47].

4.3.2. Radiological Outcome

Woods *et al.* [47] reported that laminectomy reduced the average cervical lordosis by 2.57 degrees while laminoplasty increased the average cervical lordosis by 0.57 degrees.

A recent study by Liu *et al.* [33] reported that both techniques resulted in no difference in postoperative cervical curvature index and cervical Cobb's angle. However, the authors [33] suggested to select laminectomy with fusion in severe preoperative cervical kyphotic patients.

4.3.3. Surgical Outcome

Several studies compared the surgical outcome between these procedures. The parameters were operation time and complication.

The meta-analysis study by Liu *et al.* [33] reported that laminoplasty exhibited shorter operation time than laminectomy. Similarly, Lao *et al.* [48] also noted that the average operation time in laminoplasty was shorter than laminectomy (137.4 min and 142.6 min, respectively). However, the difference was not statistically significant.

There are several studies that compared postoperative complication between these techniques. Lao *et al.* [48] conducted a systematic review that compared the complications in laminoplasty and laminectomy. They found that both procedures caused several complications including kyphosis, C5 paresis, infection, subluxation, instability, CSF leakage, wound dehiscence, urinary retention, chronic pain, restenosis, nonunion, hardware failure, and revision surgery. However, there was no significant difference in the complications between both techniques [33, 48]. Woods *et al.* [47] reported laminoplasty exhibited

higher incidence of complication (13%) than laminectomy and fusion (9%). However, the variation of complication was higher in laminectomy and fusion.

The incidence of C5 palsy was lower in laminoplasty [33]. Wang *et al.* [27] reported that laminectomy and fusion exhibited the highest rate of C5 palsy (15.2%). This is probably because laminectomy and fusion cause more posterior shift of the spinal cord than laminoplasty. Posterior shift can stretch the C5 root and injure the nerves.

They also compared the incidences of axial pain and found no difference between both techniques [27, 33].

5. CONCLUSION

The pathophysiology of CSM can generally be classified into static and dynamic factors that can further cause ischemia. Posterior osteophyte is the most common cause of CSM in elderly. All surgical techniques have their advantages and disadvantages. In anterior approaches, ACDF seems more superior than ACCF in terms of clinical, radiological, and surgical outcomes. However, ACCF is required when the pathologies are adjacent to the vertebral body. In posterior approaches, it seems that both techniques result in similar outcomes; deciding the technique to be used depends on the preference of the surgeon.

References

- Mattei TA, Goulart CR, Milano JB, Dutra LPF, Fasset DR. Cervical spondylotic myelopathy: Pathophysiology, diagnosis, and surgical techniques. *ISRN Neurology*. 2011. doi:10.5402/2011/463729
- Mullin J, Shedid D, Benzel E. Overview of cervical spondylosis pathophysiology and biomechanics. *World Spinal Column J*. 2011; 2(3)
- Lebl DR, Hughes A, Cammisia FP, O'Leary PE. Cervical spondylotic myelopathy: pathophysiology, clinical presentation, and treatment. *HSSJ*. 2011; 7:170-8. doi:10.1007/s11420-011-9208-1
- Karadimas SK, Erwin WM, Ely CG, Dettori JR, Fehlings MG. Pathophysiology and natural history of cervical spondylotic myelopathy. *SPINE*. 2013; 38:S21-36. doi:10.1097/BRS.0b013e3182a7f2c3
- Hsu W, Dorsi MJ, Witham TF. Surgical Management of cervical spondylotic myelopathy. *Neurosurg Quat*. 2009; 19(4):302-07. doi:10.1097/WNQ.0b013e3181bd5f8c
- Dolan RT, Butler JS, O'Byrne JM, Poynton AR. Mechanical and cellular processes driving cervical myelopathy. *World J Orthop*. 2016; 7(1):20-9.
- Kiely PD, Quinn JC, Du JY, Lebl DR. Posterior surgical treatment of cervical spondylotic myelopathy. *HSSJ*. 2015; 11:36-42. doi:10.1007/s11420-014-9425-5
- Lu J, Wu X, Li Y. Surgical results of anterior corpectomy in the aged patients with cervical myelopathy. *Eur Spine J*. 2008; 17:129-35. doi:10.1007/s00586-007-0518-4
- Guan L, Hai Y, Yang J-C, Zhou L-J, Chen X-L. Anterior cervical discectomy and fusion may be more effective than anterior cervical corpectomy and fusion for the treatment of cervical spondylotic myelopathy. *BMC Musculoskelet Disord*. 2015; 16:29. doi:10.1186/s12891-015-0490-9
- Liu T, Xu W, Cheng T, Yang H-L. Anterior versus posterior surgery for multilevel cervical myelopathy, which one is better? A systemic review. *Eur Spine J*. 2011; 20:224-35. doi:10.1007/s00586-010-1486-7
- Zhu B, Xu Y, Liu X, Liu Z, Dang G. Anterior approach versus posterior approach for the treatment of multilevel cervical spondylotic myelopathy: a systemic review and meta-analysis. *Eur Spine J*. 2013; 22:1583-93. doi:10.1007/s00586-013-2817-2
- Kavanagh RG, Butler JS, O'Byrne JM, Poynton AR. Operative techniques for cervical radiculopathy and myelopathy. *Adv Orthop*. 2012; 2012:916149. doi:10.1155/2012/794087
- Alimi M, Njoku I, Hofstetter CP, Tsiouris AJ, Kesavabhotla K, *et al.* Anterior Cervical Discectomy and Fusion (ACDF): comparison between zero profile implants and anterior cervical plate and spacer. *Cureus*. 2016; 8(4):e573. doi:10.7759/cureus.573
- Haghnegahdar A, Sedighi M. An outcome study of anterior cervical discectomy and fusion among Iranian population. *Neurosci J*. 2016; 2016:4654109. doi:10.1155/2016/4654109
- Fei Q, Li J, Su N, Wang B, Li D, *et al.* Comparison between anterior cervical discectomy with fusion and anterior cervical corpectomy with fusion for the treatment of cervical spondylotic myelopathy: a meta-analysis. *Ther Clin Risk Manag*. 2015; 11:1707-18. doi:10.2147/TCRM.S94290
- Wang T, Wang H, Liu S, An H-D, Liu H, *et al.* Anterior cervical discectomy and fusion versus anterior cervical corpectomy and fusion in multilevel cervical spondylotic myelopathy. *Medicine*. 2016; 95:49(e5437). doi:10.1097/MD.0000000000005437
- Huang Z-Y, Wu A-M, Li Q-L, Lei T, Wang K-Y, *et al.* Comparison of two anterior fusion methods in two-level cervical spondylosis myelopathy: a meta-analysis. *BMJ Open*. 2014; 4:e004581. doi:10.1136/bmjopen-2013-004581
- Han Y-C, Liu Z-Q, Wang S-J, Li L-J, Tan J. Is anterior cervical discectomy and fusion superior to corpectomy and fusion for treatment of multilevel cervical spondylotic myelopathy? A systemic review and meta-analysis. *PLoS One*. 2014; 9(1):e87191. doi:10.1371/journal.pone.0087191
- Wen Z-Q, Du J-Y, Ling Z-H, Xu H-D, Lin X-J. Anterior cervical discectomy and fusion versus anterior cervical corpectomy and fusion in the treatment of multilevel cervical spondylotic myelopathy: systemic review and a meta-analysis. *Ther Clin Risk Manag*. 2015; 11:161-70. doi:10.2147/TCRM.S72699
- Han SY, Kim HW, Lee CY, Kim HR, Park DH. Stand-alone cages for anterior cervical fusion: Are there no problems? *Korean J Spine*. 2016; 13(1):13-9. doi:10.14245/kjs.2016.13.1.13
- Sun Y, Muheremu A, Yan K, Yu J, Zheng S, *et al.* Effect of different surgical methods on headache associated with cervical spondylotic myelopathy and/or radiculopathy. *BMC Surg*. 2015; 15:105. doi:10.1186/s12893-015-0092-3

22. Chong E, Pelletier MH, Mobbs RJ, Walsh WR. The design evolution of interbody cages in anterior cervical discectomy and fusion: a systematic review. *BMC Musculoskelet Disord.* 2015; 16:99. doi:10.1186/s12891-015-0546-x
23. Fengbin Y, Xinwei W, Haisong Y, Chen Y, Xiaowei L, Deyu C. Dysphagia after anterior cervical discectomy and fusion: a prospective study comparing two anterior surgical approaches. *Eur Spine J.* 2013; 22:1147-51. doi:10.1007/s00586-012-2620-5
24. Ha SM, Kim JH, Oh SH, Song JH, Kim HI, *et al.* Vertebral distraction during anterior cervical discectomy and fusion causes postoperative neck pain. *J Korean Neurosurg Soc.* 2013; 53:288-92. doi:10.3340/jkns.2013.53.5.288
25. Gao R, Yang L, Chen H, Liu Y, Liang L, *et al.* Long term results of anterior corpectomy and fusion for cervical spondylotic myelopathy. *PLoS One.* 2012; 7(4):e34811. doi:10.1371/journal.pone.0034811
26. Chacko AG, Joseph M, Turel MK, Prabhu K, Daniel RT, *et al.* Multilevel oblique corpectomy for cervical spondylotic myelopathy preserves segmental motion. *Eur Spine J.* 2012; 21:1360-67. doi:10.1007/s00586-011-2137-3
27. Wang T, Tian X-M, Liu S-K, Wang H, Zhang Y-Z, *et al.* Prevalence of complications after surgery in treatment for cervical compressive myelopathy: a meta-analysis for last decade. *Medicine.* 2017; 96:12(e6421). doi:10.1097/MD.0000000000006421
28. Jain A, Rustagi T, Prasad G, Deore T, Bhojraj SY. Does segmental kyphosis affect surgical outcome after a posterior decompressive laminectomy in multisegmental cervical spondylotic myelopathy? *Asian Spine J.* 2017; 11(1):24-30. doi:10.4184/asj.2017.11.1.24
29. Zhang P, Shen Y, Zhang Y-Z, Ding W-Y, Xu J-X, *et al.* Preserving the C7 spinous process in laminectomy combined with lateral mass screw to prevent axial symptom. *J Orthop Sci.* 2011; 16:492-97. doi:10.1007/s00776-011-0115-6
30. Chang V, Lu DC, Hoffman H, Buchanan C, Holly LT. Clinical results of cervical laminectomy and fusion for the treatment of cervical spondylotic myelopathy in 58 consecutive patients. *Surg Neurol Int.* 2014; 5(Suppl 3):S133-7. doi:10.4103/2152-7806.130670
31. Laiginhas ARA, Silva PA, Pereira P, Vaz R. Long-term clinical and radiological follow-up after laminectomy for cervical spondylotic myelopathy. *Surg Neurol Int.* 2015; 6:162. doi:10.4103/2152-7806.167211
32. Woods BI, Hohl J, Lee J, Donaldson III W, Kang J. Laminoplasty versus laminectomy and Fusion for multilevel cervical spondylotic myelopathy. *Clin Orthop Relat Res.* 2011; 469:688-95. doi:10.1007/s11999-010-1653-5
33. Liu F-Y, Yang S-D, Huo L-S, Wang T, Yang D-L, *et al.* Laminoplasty versus laminectomy and fusion for multilevel cervical compressive myelopathy: a meta-analysis. *Medicine.* 2016; 95:23(e3588). doi:10.1097/MD.0000000000003588
34. Uehara M, Takahashi J, Ogiwara N, Hirabayashi H, Hashidate H, *et al.* Cervical pedicle screw fixation combined with laminoplasty for cervical spondylotic myelopathy with instability. *Asian Spine J.* 2012; 6(4):241-8. doi:10.4184/asj.2012.6.4.241
35. Shin J-W, Jin S-W, Kim S-H, Choi J-I, Kim B-J, *et al.* Predictors of outcome in patients with cervical spondylotic myelopathy undergoing unilateral open-door laminoplasty. *Korean J Spine.* 2015; 12(4):261-6. doi:10.14245/kjs.2015.12.4.261
36. Su N, Fei Q, Wang B, Li D, Li J, *et al.* Long-term outcomes and prognostic analysis of modified open-door laminoplasty with lateral mass screw fusion in treatment of cervical spondylotic myelopathy. *Ther Clin Risk Manag.* 2016; 12:1329-37. doi:10.2147/TCRM.SI 10340
37. Cho Y. The change of range of motion at anterior compression of the cervical cord after laminoplasty in patients with cervical spondylotic myelopathy. *Korean J Spine.* 2016; 13(4):177-82. doi:10.14245/kjs.2016.13.4.177
38. Yeh K-T, Yu T-C, Chen I-H, Peng C-H, Liu K-L, *et al.* Expansive open-door laminoplasty secured with titanium miniplates is a good surgical method for multiple-level cervical stenosis. *J Orthop Surg Res.* 2014; 9:49.
39. Yeh K-T, Lee R-P, Chen I-H, Yu T-C, Peng C-H, *et al.* The midterm surgical outcome of modified expansive open-door laminoplasty. *BioMed Res Int.* 2016. doi:10.1155/2016/8069354
40. Sakaura H, Hosono N, Mukai Y, Iwasaki M, Yoshikawa H. C3-6 Laminoplasty for cervical spondylotic myelopathy maintains satisfactory long-term surgical outcomes. *Global Spine J.* 2014; 4:169-74. doi:10.1055/s-0034-1381727
41. Son DK, Son DW, Song GS, Lee SW. Effectiveness of the laminoplasty in the elderly patients with cervical spondylotic myelopathy. *Korean J Spine.* 2014; 11(2):39-44. doi:10.14245/kjs.2014.11.2.39
42. Heller JG, Raich AL, Dettori JR, Riew KD. Comparative effectiveness of different types of cervical laminoplasty. *Evid Based Spine Care J.* 2013; 4:105-15. doi:10.1055/s-0033-1357361
43. Mesfin A, Park M-S, Piyaskulkaew C, Chuntarapas T, Song KS, *et al.* Neck pain following laminoplasty. *Global Spine J.* 2015; 5:17-22. doi:10.1055/s-0034-1394297
44. Sun Y, Muheremu A, Yan K, Yu J, Zheng S, *et al.* Effect of double-door laminoplasty on atypical symptoms associated with cervical spondylotic myelopathy/radiculopathy. *BMC Surg.* 2016; 16:31. doi:10.1186/s12893-016-0146-1
45. Kim S-H, Kim E-S, Eoh W, Jang IT, Choi S-E. Is the cross-sectional area after unilateral open door laminoplasty wider than that after midline splitting laminoplasty?: math approach. *Korean J Spine.* 2013; 10(4):237-41. doi:10.14245/kjs.2013.10.4.237
46. Hirabayashi S, Yamada H, Motosuneya T, Watanabe Y, Miura M, *et al.* Comparison of enlargement of the spinal canal after cervical laminoplasty: open-door type and double-door type. *Eur Spine J.* 2010; 19:1690-94. doi:10.1007/s00586-010-1369-y
47. Warren DT, Ricart-Hoffiz PA, Andres TM, Hoelscher CM, Protopsaltis TS, *et al.* Retrospective cost analysis of cervical laminectomy and fusion versus cervical laminoplasty in the treatment of cervical spondylotic myelopathy. *Int J Spine Surg.* 2013; 7:e72-e80. doi:10.1016/j.ijsp.2013.04.001
48. Lao L, Zhong G, Li X, Qian L, Liu Z. Laminoplasty versus laminectomy for multi-level cervical spondylotic myelopathy: a systemic review of the literature. *J Orthop Surg Res.* 2013; 8:45.

Citation: Mardhika PE, Marta KKA, Maliawan S, Mahadewa TGB. Cervical spondylotic myelopathy: pathophysiology and surgical approaches. *Recent Adv Biol Med.* 2017; 3:86-94.