

E-ISSN: 2378-654X

Recent Advances in Biology
and Medicine

Mini Review

Marjolin's Ulcer: A
Malignant Complication of
Burn Wound

HATASO

Marjolin's Ulcer: A Malignant Complication of Burn Wound

Bertha Kawilarang*

Faculty of Medicine, Universitas Pelita Harapan, Tangerang, Indonesia.

*Correspondence: berthakawilarang12@gmail.com

Received: Nov 15, 2019; Accepted: Feb 4, 2020

Copyright: Bertha Kawilarang. This is an open-access article published under the terms of Creative Commons Attribution License (CC BY). This permits anyone to copy, distribute, transmit, and adapt the work, provided the original work and source are appropriately cited.

Citation: Kawilarang B. Marjolin's ulcer: A malignant complication of burn wound. *Recent Adv Biol Med.* 2020; 6(1): 960446. <https://doi.org/10.18639/RABM.2020.960446>

Abstract

Marjolin's ulcer is a rare malignancy found in nonhealing chronic wounds, with burn injury as the most common predisposing factor. It is an aggressive malignancy that has a long latency period, and it is diagnosed through clinical findings, histopathology, and imaging modalities. Prompt surgical treatment and proper burn wound care strategies are key to prevent further complications and increase in mortality.

Keywords: Marjolin's ulcer; Malignancy; Burn; Wound.

1. INTRODUCTION

Marjolin's ulcer is defined as a malignant change of skin with previous trauma or chronic inflammation [1]. The term was derived from observations during the first century by French surgeon Jean-Nicolas Marjolin [2]. In 1838, a study by Dupuytren observed that a Belgian man had cancer because of a scar that resulted from a sulfuric acid burn [3]. The name itself was published in 1850 by Robert Smith, who described it as cellular changes occurring in the ulcerated lesion of burn scar [4].

Marjolin's ulcer is a rare complication, but it is a highly aggressive type of squamous cell carcinoma (SCC) that develops in burn scar tissue [1, 2]. However, other lesions that may also develop into Marjolin's ulcer are chronic pressure ulcers, skin graft donor sites, frostbites, and neuropathic ulcers, among others [2]. It can be found in all age groups, with the average age of patients being approximately 50 years [2], while a study reported that the average age of onset is from 53 to 59 years [5]. The transformation from being an initial lesion to becoming a malignant ulcer progresses slowly [6], with studies reporting a latency period of at least 2-3 decades for the transformation to take place [2].

2. EPIDEMIOLOGY

The incidence of Marjolin's ulcers ranges from 1% to 2% of all burn scars [6], with SCC as the most common histology type [7]. A study reported that 82.5% of the etiologic factor is due to burn scars [1], making burns as the most common etiology [4]. This is supported by a retrospective study of a 4-year period, which revealed that the highest cause was initial injury due to flame burns, followed by abnormal growth of skin mass, trauma, and ulceration from repeated friction [8].

There is a lack of global data, as reported cases came from certain countries only, namely, China, India, Turkey, and Iran [9]. However, there is presumably a difference in incidence rates due to sociocultural and economic influences [5]. Many of these cases originate in developing countries where there is tendency for wound neglect and thus late presentations [10]. In the sub-Saharan population, neglected burn scars cause up to 63% of SCCs [5]. In Japan, Marjolin's ulcer is known as "Kairo burn cancer," which is a malignancy occurring due to the practice of wearing tin ovens in the abdomen covered under a garment [5]. Similarly, in northwestern China, the term "kang ulcers" refers to ulcers in the buttocks region as a result of the tradition of warming the bed with an external heat source [5]. In the Indian population, kangri ulcers result from placing earthen firepots called kangri underneath traditional clothing [5]. Up to 6.8% of Indians have reported this case of malignancy [5, 6].

3. PATHOGENESIS

There are different hypotheses for the pathophysiology of Marjolin's ulcers, and it is possible that multiple mechanisms play a role. Healed burn injury, which undergoes secondary intention, is thought to be at increased risk due to continuous injury from daily activities. This is so as there is loss of protection from the normal dermis, nerves, and vessels [11]. These features make skin much less elastic, thus making it more susceptible to being injured and ulcerated than normal skin [11]. A study by Treves and

2 Mini Review

Pack [5, 11] postulated that burn eschars release tissue toxins through autolysis. Additionally, there is poor vascularization of tissue surrounding the lesion, and these two factors predispose the burn tissue scar to ulceration [11]. This conforms with Ewing's postulates, which described the criteria a tumor needs to fulfill for it to qualify as a postburn malignancy [12]. The five criteria postulated are as follows: the cancer originates within the boundary of a scar or wound site, there is existing evidence of trauma or a preexisting ulcer, there is absence of prior neoplasm on the lesion site, histological features associated with the tissue found in the site of a wound or scar, and presence of an interval time between ulcer to cancer development of a minimum of 1-month duration [5, 7, 9]. Other proposed theories include the cocarcinogen theory by Friedwald and Rouse, theory of epithelial implantation by Ribet, and immunologically privileged site theory by Castillo and Goldsmith [13]. However, none of these postulated theories can demonstrate the entirety of Marjolin's ulcer pathogenesis [13].

There are two forms of Marjolin's ulcers: acute and chronic type [5, 11]. The acute type is rarely reported, as it develops in less than a year after burn injury causes a lesion [11]. A study found that the acute type usually occurs on small and superficial burn tissues, forming the basal cell carcinoma [1, 2]. The chronic type is rather more common, and it typically develops more than a year after the injury [1, 2]. In a case series study, chronic lesions developed into scars within a duration of 5 years, which then underwent an average latency period of 37.9 years [1]. However, classifying the Marjolin's ulcer as an acute or chronic type is found to be of no benefit, since both types do not exhibit different histologic or prognostic characteristics [14].

Several risk factors that contribute to the transformation of malignancy are wound healing by secondary intention, infected wounds, fragile traumatized tissue, and poor local and systemic immune responses [10]. Prolonged healing of burn tissues is the most universal and accepted risk factor of Marjolin's ulcer [1, 10], which might also explain the high prevalence in developing countries and middle-to-low socioeconomic population. However, contrary to that, a study found that Marjolin's ulcer also developed on a burn scar that was previously grafted and underwent healing [1, 15]. Nevertheless, it is always important to raise suspicion on these findings during history taking in order to obtain early diagnosis.

4. HISTOPATHOLOGY

In regard to the histopathological findings, Marjolin's ulcer can be classified into SCC, basal cell carcinoma, melanoma, sarcoma, and other rare subtypes [8]. The most prevalent type is SCC, which makes up 80%-90% of all cases, followed by basal cell carcinoma (9.6%) and melanoma (2.4%) [16]. A small proportion of other cases that have been described are sarcoma, dermatofibrosarcoma, mucoepidermoid carcinoma, and leiomyosarcoma [16]. The lesion site also affects the histopathology of ulcer. Ulcers found on lower limbs are mainly of the SCC type, while those on the trunk region are dermatofibrosarcoma protuberans, and ulcers on facial region are mostly basal cell carcinoma [8]. Generally, Marjolin's ulcer may present in any part of the skin surface; however, the most common sites reported are lower limbs, followed by the head, the neck, and upper limbs [8].

Marjolin's ulcer is aggressive and has a high potency for metastasis [7]. Rate of metastasis in the SCC type is up to 54% of cases [17]. Marjolin's ulcer presents with two different growth patterns [18]. The most common type is the ulcerative carcinoma, which is seen under the microscope as flat, indurated, and infiltrative [18], while a less frequent type is the exophytic papillary form [18]. The ulcerative carcinoma type typically presents with a poorer outcome as its presence is often insidious and begins with only painful sensation [5]. It might produce hemorrhagic discharge in the later stages; however, the extension of the ulcer is somewhat difficult to recognize [5].

5. DIAGNOSIS

Diagnosis of Marjolin's ulcer is made through physical examination of clinical findings, histopathological findings through biopsy, and imaging modalities, if indicated.

5.1. Clinical Presentation

Careful physical examination should evaluate old scars, particularly those lasting for more than 3 months in any part of the body [7]. A Marjolin's ulcer typically presents as an indurated lesion with elevated margins in an area of the chronic wound or scar [16] (Figures 1 and 2). A triad of common symptoms includes the formation of nodules, induration, and ulceration [19]. Other signs might involve pain, easy bleeding upon disruption, and foul-smelling pus, which may involve granulation tissue and regional lymphadenopathy [19]. Therefore, a physical examination of all lymph nodes must also be performed. Generally, a chronic nonhealing ulcer protruding over a previous long-term scar, which fulfills the triad, should warrant a diagnosis of Marjolin's ulcer until proven otherwise [20]. Most common anatomical sites are the extremities, particularly lower limbs, scalp, and neck [13, 20]. Other rare sites that have been reported are the nose, lip, and eyelids, which are all prone to burn scar malignancies [20]. It is important that all areas are examined thoroughly as some might present as atypical cases, which can easily be misdiagnosed as general scar ulcers [8].

5.2. Biopsy

Due to the nature of Marjolin's ulcer, which is a malignancy transformation, a biopsy is needed as a gold standard tool for early diagnosis and prevention of potentially fatal metastasis [21, 22]. Hence, any lesion presenting as a chronic, nonhealing ulcer

Figure 1: Reported case of Marjolin's ulcer in thigh region due to burn injury that occurred 7 years ago [13].

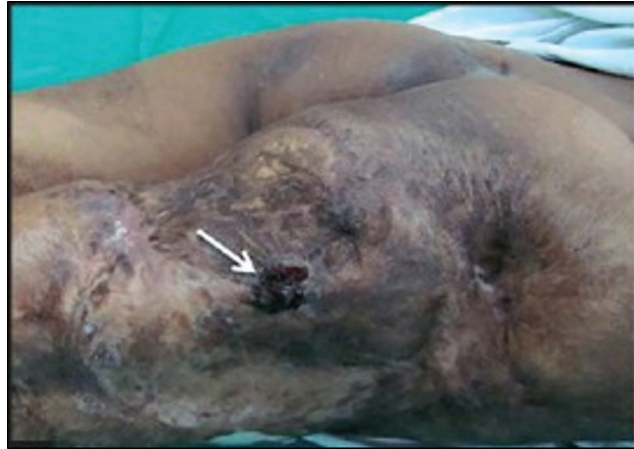
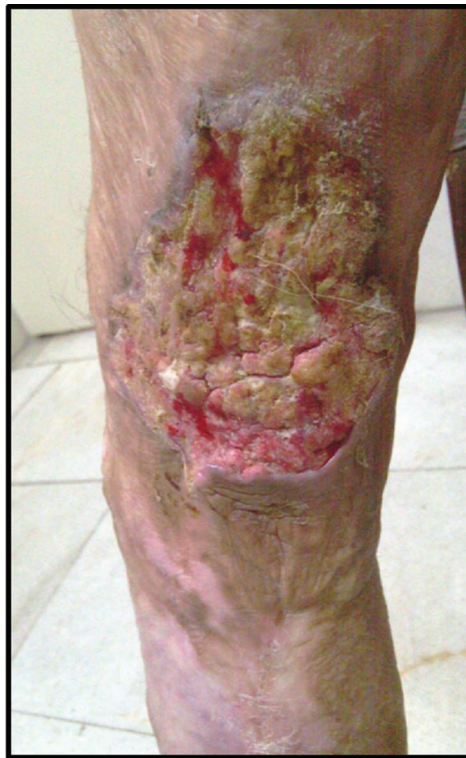
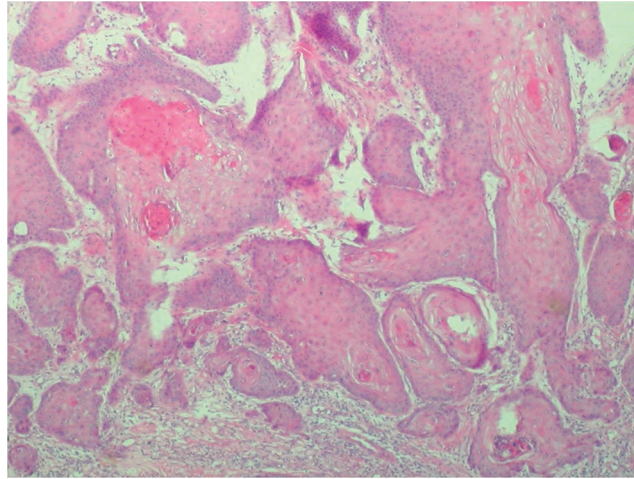
Figure 2: Reported case of Marjolin's ulcer in lower limb due to previous burn scar [11]



must undergo biopsy to obtain pathologic interpretation based on the World Health Organization's criteria for grading SCC [19]. A study recommended that there should be a repeated number of biopsies before surgery, particularly with increasing diameters of skin lesions [1, 23]. Tissue samples collected should involve the center of the lesion as well as margins of the wound [24].

A punch biopsy is regarded as a useful modality, with samples taken from any suspected site of the wound to prevent false negative results [21]. Although there is no sufficient literature to recommend standardized biopsy, a study reported that punch biopsy should be avoided due to the focal nature of the malignancy in burn scar [25]. Alternatively, studies have used incisional biopsies or wedge biopsies as recommended by the Scottish Intercollegiate Guidelines Network clinical guidelines [26]. Another study stated that excisional biopsy should be initially performed according to the size of the primary tumor [23]. For lesions less than 2.5 cm diameter, two random tumor zones are sufficient for biopsy samples, while for lesions between

Figure 3: A case of well-differentiated squamous cell carcinoma with infiltrative pattern areas and keratin pearl formation [10].



2.5 and 5 cm diameter, it is suggested that four biopsies are collected from the directions corresponding to the 3, 6, 9, and 12 o'clock sites [23]. Lesions larger than 5 cm should receive a minimum of six biopsies corresponding to the directions of 2, 4, 6, 8, 10, and 12 o'clock sites [23]. Other techniques such as the sentinel lymph node biopsy are useful for the screening for lymph node metastasis in patients with SCC -type Marjolin's ulcers [27]. Histopathological features found in biopsy are keratin pearl formation (Figure 3), lymphatic permeation, pseudoepitheliomatous hyperplasia, and perineural infiltration, among others [21].

5.3 Laboratory

Aside from the routine laboratory tests performed as part of preoperative assessment, cultures should also be obtained from Marjolin's ulcers with signs of infection, in order to specify the causative organism as well as to determine the antimicrobial regimen [21, 28]. A study reported that *Staphylococcus aureus* might be the dominant bacteria in osteomyelitis; however, none were present in SCC lesions [28]. This study supported the hypothesis that the malignancy has an inhibitory mechanism, which limits proliferation of *S. aureus* [21, 28].

5.4 Imaging

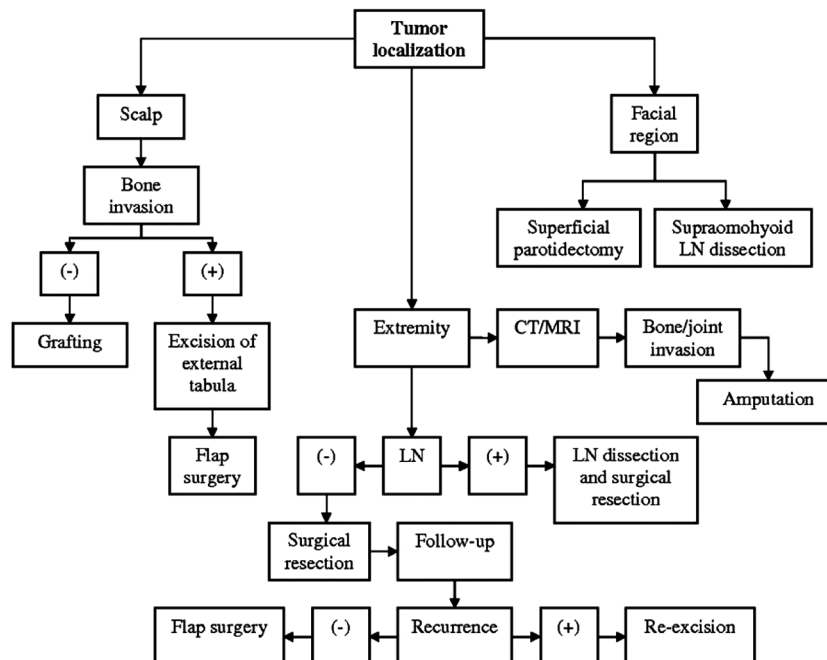
To evaluate any involvement of deeper soft tissues, several imaging modalities such as plain radiographs, computed tomography (CT) scan, and magnetic resonance imaging (MRI) can be utilized [5]. While CT scans have a higher sensitivity rate in visualizing skeletal involvement, MRI plays a greater role in detecting soft tissue involvement [5]. Additionally, these imaging techniques can be used to delineate any extension of bone destruction, soft tissue mass, or periosteal reaction [26]. However, these modalities are not essential for diagnosis of Marjolin's ulcer [26]. Positron emission tomography (PET)-CT scan, on the other hand, can be used to detect lymph node metastasis in cases of malignant melanoma type [28].

6. TREATMENT

To date, there is no agreed management plan for Marjolin's ulcer, as it typically depends on biopsy staging, clinical assessment, and CT results, if available [23, 29]. The mainstay management of Marjolin's ulcer is wide local excision along with skin grafting in most cases [26]. Due to the aggressive nature of Marjolin's ulcer, the recommended technique is wide excision of at least 2 cm up to 4 cm of clear margins [5, 22, 24]. Other literature analyses have reported that for safety reasons and prevention of further complications, a 2.5-cm wide margin should be resected in recurrent ulcers [30]. The use of Mohs micrographic surgical technique is suggested, where during the excision, removed tumors are simultaneously examined under the microscope to ensure that all malignant tissue have been excised properly [24]. It is a useful technique to make sure that all malignant tissues are completely removed.

Skin graft is more preferred than local flap alternatives, as donor sources can be preserved for future possible surgeries [1]. Although its use is limited to weight-bearing areas and noncosmetic regions, other benefits of skin grafts are shorter duration of surgery and reduced rate of morbidity [1, 26]. However, for complex cases, where the wound bed is not suitable due to exposed bone or vital structures and poorly vascularized tissues, reconstructions with free tissue transfer are performed [26]. It is advisable that there is at least a one-year interval between tumor excision and definitive reconstruction techniques to take

Figure 4: Treatment algorithm for evaluation and planning of Marjolin's ulcer [23].



CT, computed tomography; LN, lymph node; MRI, magnetic resonance imaging.

place in order to avoid local tumor recurrences [5]. Limb amputations may be required in advanced stages, which often occur in developing countries [26]. Amputation is best carried out in cases where ulcers have eroded the underlying tissues and deep vessels, posing a higher risk of metastasis, where excision alone will no longer be effective [23, 24]. The survival rate of cases that underwent wide excision with free margins is 60%, while in cases of limb amputation, it is 69% [6].

Another study has suggested the use of evaluation and treatment planning for Marjolin's ulcer based on tumor-localization site, involvement of lymph node, or other CT or MRI findings [23] (Figure 4).

While Marjolin's ulcer does not easily metastasize, if it does occur, the main pathway is through the lymphatic system [7]. Regarding the issue of lymph node dissection, studies have proposed dissection only when palpable nodes are clinically present or biopsy shows histologically high-grade tumors [1, 16]. Another study has suggested lymph node dissection as a prophylactic procedure since the nature of Marjolin's ulcer is aggressive, particularly in lesions in lower limbs [1]. Lymph node dissection is thought to be beneficial as there is a low salvage rate for regional node metastases [5, 21]. Nevertheless, lymph node dissection should be considered when there is a suspicion of lymph node metastasis involvement [13].

Other treatment modalities include 5-fluorouracil (5-FU), which reportedly had been successful for treating Marjolin's ulcer without bone invasion [13]. Another study reported that response to radiotherapy is poor although it can be used as a palliative method in recurrent or inoperable tumors [5, 9]. Adjuvant radiotherapy can be used in cases of local recurrence of tumors, unresectable lesions, invasion of extracapsular lymph nodes, or positive surgical margins [1]. However, it must be noted that radiotherapy alone is not recommended, as fibrosis and damaged tissues resulting from radiation damage will create poor vascular supply and interfere with normal wound healing [1, 11]. Any treatment plan must also coincide with proper local wound care in order to limit foul-smelling odor, and manage the bleeding site, excessive exudate production, and pain [24]. Patient and family members must be educated and advised for routine follow-up with healthcare providers as there is a high chance of recurrence and possible metastases in the long-term [24].

7. PREVENTION

Marjolin's ulcer is somewhat preventable the same way by which wound degeneration can be prevented from transforming into malignant SCC. Providing early definitive wound coverage is a key principle for skin following burns or other trauma injuries [3]. Early skin grafting should be done for deep burn wounds, while early excision and grafting are recommended for all unstable scars that are susceptible to further trauma, such as scars located at the joint or other mobile regions [13]. Additionally, thick scars with hypopigmentation must also be excised and grafted [13]. If closure is not yet feasible, wound care and its repeated evaluation must be done in the long term to monitor and prevent changes toward malignancy [10]. Special attention should

6 Mini Review

be paid to scars at the scalp area, which should be covered from sunlight by clothing or using wigs [13]. For prompt diagnosis, biopsy examination should be considered in any suspecting lesions. Due to the high rate of recurrence in high-risk types such as SCC, frequent follow-up is needed for at least a 2-year duration [7].

8. CONCLUSION

Marjolin's ulcer is a rare but aggressive malignancy of predominantly the SCC type. Care must be taken in postburn injury lesions, as they are the common predisposing factor of Marjolin's ulcer. Hence, it is important that early wound coverage is conducted in all burn wounds. Although the appearance might mimic other typical scars, indicative signs and symptoms, such as nonhealing ulcer lasting more than 3 months, foul-smelling lesion, easily bleeding on contact, presence of granulation tissue, and pain sensation, must not be overlooked. All ulcers pose a risk for recurrence and metastasis, and lesions particularly in lower limbs are associated with poor prognosis. Prompt diagnosis, treatment, and close follow-up must be done in all cases of Marjolin's ulcer.

Conflict of Interest

There is no conflict of interest.

References

1. Oruc M, Kankaya Y, Sungur N, Ozer K, Isik V, *et al.* Clinicopathological evaluation of Marjolin ulcers over two decades. *Kaohsiung J Med Sci.* 2017; 33(7):327-33.
2. Tobin C, Sanger J. Marjolin's ulcers: a case series and literature review. *Wounds.* 2014; 26(9):248-54.
3. Alhysoni K, Bukhari S, Hajjaj M. Acute Marjolin's ulcer in a postauricular scar after mastoidectomy. *Case Rep Otolaryngol.* 2016; 2016:1-5.
4. Nanze Y, Long X, Lujan-Hernandez J, Hassan K, Bai M, *et al.* Marjolin's ulcer: a preventable malignancy arising from scars. *World J Surg Oncol.* 2013; 11(313):1-7.
5. Opara K, Otene I. Marjolin's ulcers: a review. *Niger Heal J.* 2011; 11(4):107-11.
6. Mago V, Kochhar N. Marjolin's ulcer in burn scars. *Clin Res Dermatol.* 2019; 2(1):1-2.
7. Chaturvedi G, Gupta A, Das S, Gohil A, Lamba S. Marjolin ulcer: an observational epidemiological study from a tertiary care centre in India. *Ann Plast Surg.* 2019; 83(5):518-22.
8. Xiang F, Song H, Huang Y. Clinical features and treatment of 140 cases of Marjolin's ulcer at a major burn center in southwest China. *Exp Ther Med.* 2019; 7(5):3403-10.
9. Metwally I, Roshdy A, Saleh S, Ezzat M. Epidemiology and predictors of recurrence of Marjolin's ulcer: experience from Mansoura University. *Ann R Coll Surg Engl.* 2017; 99(3):245-9.
10. Cocchetto V, Magrin P, Paula R, Aide M, Razo L, *et al.* Squamous cell carcinoma in chronic wound: Marjolin ulcer. *Dermatol Online J.* 2013; 19(2):7.
11. Fazeli M, Lebaschi A, Hajiostam M, Keramati M. Marjolin's ulcer: clinical and pathologic features of 83 cases and review of literature. *Med J Islam Repub Iran.* 2013; 27(4):215-24.
12. Singh N, Rao S, Jain S. Post-burn duct carcinoma breast: an unusual case report. *J Cytol.* 2013; 30(2):139-41.
13. Challa V, Deshmane V, Reddy M. Retrospective study of Marjolin's ulcer over an eleven year period. *J Cutan Aesthet Surg.* 2014; 7(3):155-9.
14. Chang J, Kung T, Cederna P. Acute Marjolin's ulcers: a nebulous diagnosis. *Ann Plast Surg.* 2014; 72(5):515-20.
15. Turegun M, Nisanci M, Guler M. Burn scar carcinoma with longer lag period arising in previously grafted area. *Burns.* 1997; 23(6):496-7.
16. Shah M, Crane J. Marjolin ulcer [Internet]. *StatPearls.* 2019. <https://www.ncbi.nlm.nih.gov/books/NBK532861/>
17. Vazales R, Constant D, Snyder R. A rare case of aggressive digital adenocarcinoma of the lower extremity, masquerading as an ulcerative lesion that clinically favored benignancy. *Healthc.* 2014; 2(3):315-23.
18. Das S, Roy A, Maiti A. Marjolin ulcer with multifocal origin. *Indian J Dermatol.* 2009; 54(5):14-15.
19. Kerr-Valentic M, Samimi K, Rohlen B, Agarwal J, Rockwell W. Marjolin's ulcer: modern analysis of an ancient problem. *Plast Reconstr Surg.* 2009; 123(1):184-91.
20. Copcu E. Marjolin's ulcer: a preventable complication of burns? *Plast Reconstr Surg.* 2009; 124(1):156e-64e.
21. Pekarek B, Buck S, Osher L. A comprehensive review on Marjolin's ulcers: diagnosis and treatment. *J Am Col Certif Wound Spec.* 2011; 3(3):60-64.
22. Mancoll J, Phillips L. Pressure sores. In "Grabb and Smith's Plastic Surgery". 7th ed. Ediotrs - Thorne C; New York: Lippincott-Raven (2014), pp: 996-7.
23. Bozkurt M, Kapi E, Kuvat S, Ozekinci S. Current concepts in the management of Marjolin's ulcers: outcomes from a standardized treatment protocol in 16 cases. *J Burn Care Res.* 2010; 31(5):776-80.
24. Sarvis C. Marjolin's ulcer: when healing goes awry. *Nursing.* 2006; 36(4):17.
25. Parimalam K, Vinnarasan M, Senthil G, Arumugakani V, Amutha B. Marjolin's ulcer: a rare report. *Indian Dermatol Online J.* 2014; 5(5): 50-51.

26. Choa R, Rayatt S. Marjolin's ulcer. *BMJ*. 2015; 351:1-3.
27. Shen R, Zhang J, Zhang F, Du Y, Liang W, *et al*. Clinical characteristics and therapeutic analysis of 51 patients with Marjolin's ulcers. *Exp Ther Med*. 2015; 10(4):1364-74.
28. Ogawa B, Chen M, Margolis J, Schiller F, Schnall S. Marjolin's ulcer arising at the elbow: a case report and literature review. *Hand*. 2006; 1:89-93.
29. Kheiri B, Osman M, Hadidi S. From a burn scar to malignancy! Marjolin's ulcer, a disease of wound neglect. *Oxford Med Case Rep*. 2018; 2018(8):44.
30. Ghalambor A. How much of safety margin needs resection along Marjolin ulcer squamous cell carcinoma in recurrence cases? *Pak J Med Sci*. 2007; 23:394-7.